

The Chemoprevention of *Arthrospira platensis* against Diethyl nitrosamine induced Hepatocellular Carcinoma via Amelioration of Oxidative Stress in Mice

*Neelam, Priyanka Gupta and Versha Sharma

Osteoimmunology Research Lab,
Department of Zoology,
Dr. Harisingh Gour Vishwavidyalaya,
SAGAR-470003 (MP), INDIA
*Corresponding Author
E-mail : neelam981@gmail.com

Received : 01.04.2024; **Revised** : 25.04.2024; **Accepted** : 01.05.2024

ABSTRACT

Considering that natural antioxidant products do not have any negative side effects; they are an important component in the treatment and prevention of cancer. The purpose of the research was to explore whether *Arthrospira platensis* (SP) has hepatoprotective characteristics against hepatocellular carcinoma (HCC) in mice under the experimental conditions. The research was carried out with a group of fifty male Balb/c mice, they were then divided into five unique groups. Following is a list of the groups: (I) Group 1: the normal control group, (II) Group 2: Hepatocellular carcinoma (HCC) group that was induced by a single injection of Diethyl nitrosamine (DEN) at a dosage of 100 mg/kg intraperitoneally (I. P). This was followed by injections of carbon tetrachloride (CCl₄) twice a week 0.5 mg/kg body weight intraperitoneally for a total of 22 weeks, beginning 14 days after the initial injection. (III) Group 3: Oral administration of SP at a dose of 250 mg/kg was given to the HCC group. (IV) Group 4, an oral dosage of SP containing 500 mg/kg was given to the animals, whereas (V) Group 5, an oral dose of 250 mg/kg of SP was given and considered as treatment control. The data revealed that the treatment of spirulina resulted in a significant decrease in the activity of glutamate oxaloacetate transaminase (GOT) also known to be AST, glutamate pyruvate transaminase (GPT) also known to be ALT, gamma-glutamyl transaminase, and malondialdehyde (MDA). In addition, there was a notable increase in the total protein level, as well as in the activity of superoxide dismutase (SOD) and catalase (CAT), which were both much higher than normal levels. Spirulina has been shown to exhibit chemoprotective qualities, which may be linked to its antioxidant activity and its capacity to reduce lipid peroxidation has been demonstrated in every single study that has been conducted. In addition to this, it has been shown that spirulina can enhance the levels of pro-inflammatory cytokines, which in turn can significantly reduce inflammation.

Figures : 03

References : 41

Table : 00

KEY WORDS : Antioxidant; HCC; Inflammatory mediators; Oxidative stress; Spirulina

Introduction

Chronic liver disease (CLD) is a widespread disorder all over the world and is marked by a series of adverse effects, beginning with steatosis and culminating in hepatocellular carcinoma²². Liver carcinoma that is primary Hepatocellular carcinoma, often known as HCC, is the most common type of liver cancer globally²⁵. There are several significant risk factors which contribute to the development of liver cirrhosis in persons who have hepatocellular carcinoma (HCC). These risk factors include drinking alcohol, being infected with hepatitis C and B viruses²⁸ being overweight or obese, having

diabetes, and being exposed to water that has been polluted with chemicals³². It is difficult to diagnose HCC at an early stage, the prognosis is not positive, and there are no definitive treatment options available³⁰. These are the factors that contribute to the risks associated with HCC. In spite of the fact that there are traditional therapies for liver cancer (HCC), for instance chemotherapy, radiation therapy, and surgery, all of which are linked with adverse effects, liver transplantation is regarded to be the most successful treatment. On the other hand, there are considerable obstacles to overcome, such as the restricted supply of liver organs

ACKNOWLEDGEMENTS : We gratefully acknowledge and appreciate the UGC non- NET fellowship for financial support and the DST- FIST sponsored Department of Zoology, Dr. Harisingh Gour Vishwavidyalaya, Sagar- 470003 (M.P.), India for instrumentation.

and the possibility of tumour recurrence following transplant procedure³⁷. Therefore, it is of the utmost importance to make progress in the development of anticancer chemicals that are both more productive and less toxic, such as natural compounds, in order for prevention or delay the emergence of liver cancer.

Diethyl nitrosamine, often known as DEN, is a carcinogen that is found in high concentrations in a variety of environmental goods, including cheese, alcoholic drinks, soybeans, processed meat, pesticides, tobacco products, and cosmetics⁸. There is a strong correlation between the carcinogenic qualities of DEN and its capacity to create reactive oxygen species (ROS) in excessive amounts. ROS have the potential to cause damage to several biological components, including lipids, DNA, and proteins⁴¹. There is a large period of time that is required for the use of DEN as the only inducer of liver cancer. As a result, the incorporation of advancing chemicals namely carbon tetrachloride (CCl₄) becomes essential for the acceleration of the development of liver cancer¹⁸. Cellular damage can be caused by CCl₄ either by covalently coupling its reactive intermediates to the cellular constituents or also by peroxidizing membrane lipids in conjunction alongside the free radical intermediates, which eventually lead to damage to the intracellular membrane⁴. Furthermore, the p450 enzymes have the ability to enhance the dehalogenation process of CCl₄, which ultimately leads to the production of trichloromethyl radicals throughout the process. Following this, these radicals are able to be accompanied by the sulfhydryl groups of glutathione and by thiol proteins, which ultimately results in a decrement in the antioxidant defenses³⁶.

Inflammation of the liver is responsible for the majority of instances of hepatocellular carcinoma (HCC)², and there are numerous different molecular mechanism that make happen progression and malignancy of HCC²⁵. Species that are capable of interacting with DNA bases are produced as a result of oxidative and nitrative stress as well as lipid peroxidation¹⁷. This interaction leads to the production of DNA adducts, which have the potential to induce mutations, In a wide variety of malignant circumstances. Oxidative stress takes a significant part in the progression and emergence of hepatocellular carcinoma (HCC)³⁵, since it is a contributor to the migration, invasion, and dissemination of HCC¹⁰. Furthermore, oxidative stress has the ability to cause damage to hepatocytes, which can result in an increase in aberrant polyploidization and the initiation of inflammation³¹. In addition to mixed lesions that are together referred to as steatohepatitis, the outcomes of lipid peroxidation have the potential to activate stellate cells in the liver

that are responsible for the production of collagen and to result in the activation of pro-inflammatory cytokines. The degradation and death of hepatocytes, the infiltration of inflammatory cells, and the formation of fibrosis are all examples of these lesions⁸.

An example of a filamentous microalga that is classified as a member of the cyanobacterium group is the *Spirulina platensis* (SP) species. When included into a diet, it is recognized for the powerful antioxidant, anti-inflammatory, anti-cancer properties²⁴. As a result of its high concentration of protein, carbohydrates, sterols, and polyunsaturated fatty acids, as well as vital minerals as an example zinc, calcium, magnesium, iron, manganese, and selenium, it is utilised as a nutritional supplement for human consumption. Tocopherol, vitamin E, ascorbic acid, and vitamin B 12 are all found naturally in spirulina¹², a natural source of vitamin E. In the past, people from Asia, Mexico, and Africa have used it as a source of sustenance. Due to the substance's potential antioxidant, antibacterial, and antiparasitic properties, it is now the subject of a significant amount of study. The potential uses of this substance in the treatment of anextensive varieties of illness, including allergies, ulcers, anemia, heavy metal toxicity, and radiation exposure, are also being researched²¹.

Material and Methods

The hepatoprotective effects of spirulina were investigated in this study with the intention of determining whether or not they are effective against hepatocellular carcinoma (HCC) caused by diethyl nitrosamine. This was accomplished by investigating the effect that spirulina has on oxidative stress as well as the production of cytokines that are associated with inflammation.

Arthrospira platensis was obtained from (Healthy hey organic, Tamil Nadu, India). Diethyl nitrosamine (DEN), carbon tetrachloride (CCl₄), and other chemicals namely Riboflavin and Thio-barbituric acid were procured from SigmaAldrich. Additionally, AST and ALT commercial kits were ordered from company Bio diagnostics (Lucknow, India). Total protein colorimetric kits were procured from the Abcam company.

Animals

This study was carried off with the assistance of fifty male Balb/c mice with an average body weight of 20-25 g. These mice were obtained from the Department of Zoology at Banaras Hindu University, India. The mice were housed in a plastic cage, for a period of one to two weeks. This allowed them to acclimate to the laboratory environment, which included a temperature range of 22 to 25°C and a 12-hour light and dark photoperiod. Throughout the course of the study, the animals were fed a standard commercial diet and had access to water

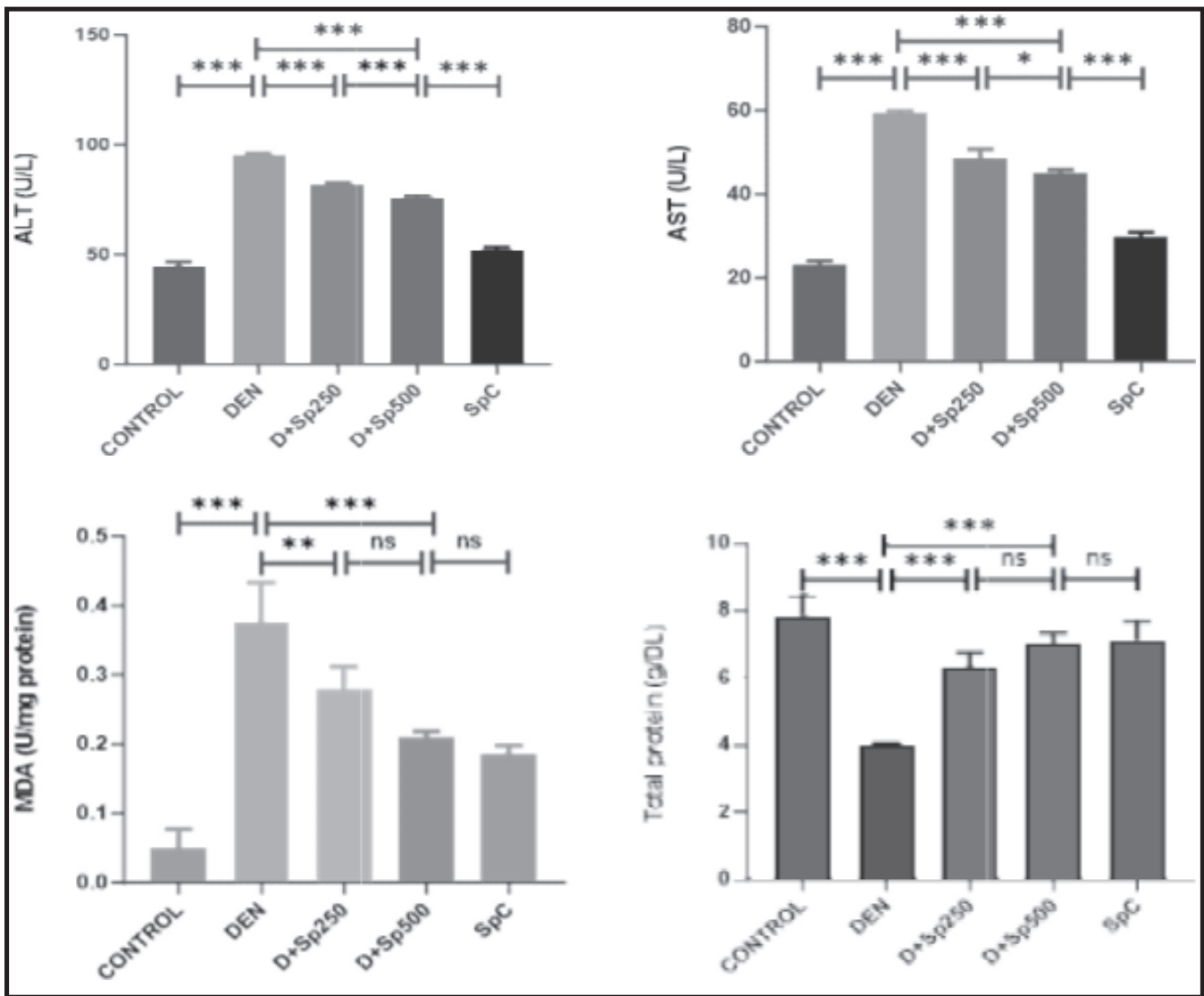


Fig. 1 : The expression of ALT, AST enzyme level, MDA and total protein was analyzed. The results were evaluated by using 1-way ANOVA. Analysis was performed using GraphPad prism software 10.0. Values are reported as mean ± SEM (n = 7) and similar results were obtained in two independent experiments. Statistical significance was defined as *P<0.05, **P<0.01, ***P<0.001, with respect to Control vs DEN+CCI₄, DEN+CCI₄ vs D+Sp250, DEN+CCI₄ vs D+Sp500, D+Sp250 vs D+Sp500, D+Sp500 vs SpC group.

ad libitum. Both the Committee for the Supervision of Experiments and Purpose of Control on Animals (CPSCEA) of India and the Institutional Animal Ethical Committee (IAEC) in India, led by Dr. Harisingh Gour Vishwavidyalaya, Sagar, (M.P.), gave their approval for the experiment.

Induction of HCC DEN model

A single dose of DEN (100 mg/kg b.wt.) was injected intraperitoneally (I.P.) to the mice participating in the experiment¹. Additionally, to induce cancer formation, CCl₄ was administered (0.5 ml/kg I.P.) biweekly, beginning 14 days after the DEN injection and continuing for 22 weeks of experiment¹⁵.

Experimental Design

Following the acclimatisation period, mice were arbitrarily allocated into five Groups using a similar method: Group (I): The mice in this group were administered 0.9% normal saline through an oral gavage. Group (II): The mice in this group were treated with DEN/CCl₄, as indicated earlier. Group (III) mice were administered a dose of 250 mg/kg of Spirulina². Group (IV) mice were administered a dosage of 500 mg/kg of Spirulina, while Group (V) served as the control group and got a dose of 250 mg/kg of Spirulina¹³. Spirulina treatment was administered daily *via* stomach tube after the induction of HCC for a duration of 8 weeks.

Biochemical Examination

At the conclusion of the 28-week study, biochemical examination was conducted. The mice were rendered unconscious by injecting thiopental sodium into their abdominal cavity at a dosage of 50 mg/kg b.w.³⁴. The blood sample for examination was obtained through the retroorbital venous plexus from mice involved in the study. It was thereafter put through centrifugation at a speed of 3000 rpm for an extent of 20 minutes to separate the serum. The serum was subsequently stored at a temperature of -20°C up to the time of the measurement of Serum Glutamate pyruvate transaminase (SGPT), Serum Glutamate oxaloacetate transaminase (SGOT)²⁰ and total protein³⁰ using quantitative colorimetric commercial kits.

Anti-oxidant Assay

The blood sample was obtained in a tube containing heparin and thereafter put through centrifugation at a speed of 4000 revolutions per minute for an extent of 15 minutes at a temperature of 4 degrees Celsius. This process was carried out to separate the plasma from the erythrocyte lysate. The resulting samples were then maintained at a temperature of -20 degrees Celsius until they were used for the oxidative/antioxidant assay. The activities of Superoxide dismutase (SOD), Lipid peroxidation (LPO), and catalase (CAT) were evaluated using the relevant procedures²⁰.

Histopathological Examination

The liver tissues sample obtained out of all mice in the experiment were prepared thereafter divided into sections aimed at histopathological investigation. The liver tissue was preserved using 10% neutral formalin, dehydrated using different alcohol concentrations, cleared with xylene, and finally placed in paraffin blocks for embedding. The sections thereafter prepared using a 6µm thickness and subsequently stained with hematoxylin and eosin (H&E)²⁹. The Leica DMRBE light microscope from Japan, equipped with a Leica DFC 295 digital camera and computer, was utilised to capture photographs of the histological alterations in the liver tissue across all experiment groups.

The Data Statistical Analysis

To verify the existence of differences between the various experimental groups, a one-way analysis of variance (ANOVA) was carried through, and a Tukey test was also carried out. This was done with the assistance of GraphPad software Inc. The p-value that is lower than 0.05 is considered as statistically significant. Further the information is provided in the form of the mean value, supplemented or subtracted by the standard error of mean (SEM).

Results

Biochemical Markers

Evidence (Fig. 1) reveals a noteworthy rise ($P < 0.001$) in the serum activity of liver function test GPT and GOT in mice that were administered DEN/CCl₄ in comparison to the normal control group. The administration of Spirulina, on the other hand, led to a noteworthy decrement ($P < 0.001$) in the levels of GPT and GOT when compared to the HCC group. Spirulina therapy did not result in any discernible differences in enzyme activity among the group that was treated as Spirulina control. On the other hand, when compared to the DEN/CCl₄ group, the enzyme activity was dramatically reduced ($P < 0.001$) by the treatment with SP, which brought it very close to the normal level.

When the group that was treated with DEN/CCl₄ was compared to the normal group, it was observed that there was a substantial decrease in the total protein level ($P < 0.001$). Particularly noteworthy is the fact that the SP treatment led to a significant rise ($P < 0.05$) in the total protein level as compared to the group that was subjected to the DEN/CCl₄. In point of fact, there was not a significant alteration seen in the enzyme activities among the group that was treated to SP control and the group that served as the normal control.

Antioxidant activity assay

In comparison to the normal group, the malondialdehyde activity shown a significant incline ($P < 0.001$) in the group that was affected by liver cancer. It is quite remarkable that the SP treatment demonstrates a significant decrement ($P < 0.001$) in the MDA activity when compared with the HCC group. On the other hand, as compared to the normal group, the group that was treated with DEN/CCl₄ exhibited a noteworthy reduction ($P < 0.0001$) in antioxidant activity, particularly in SOD and CAT. At the same time, the group that was treated with SP had a noteworthy rise ($P < 0.001$) in the levels of SOD and CAT activity as compared to the group that was treated with HCC (Fig 2). Additionally, the higher dose of *Spirulina* showed higher activity of antioxidant activity compared to lower dose of *Spirulina*.

Histopathology

According to the findings of the histological examination, the liver tissue in the normal group exhibited a structure that is normal. In contrast, the liver tissue of mice that were palliated with DEN/CCl₄ displayed a typical hepatocellular carcinoma (HCC) lesions. These lesions were distinguished by severe necrosis, polymorphic area, intense inflammation with mononuclear cells infiltration, cytoplasmic inclusion bodies, severe large vacuolar disintegration of liver cells,

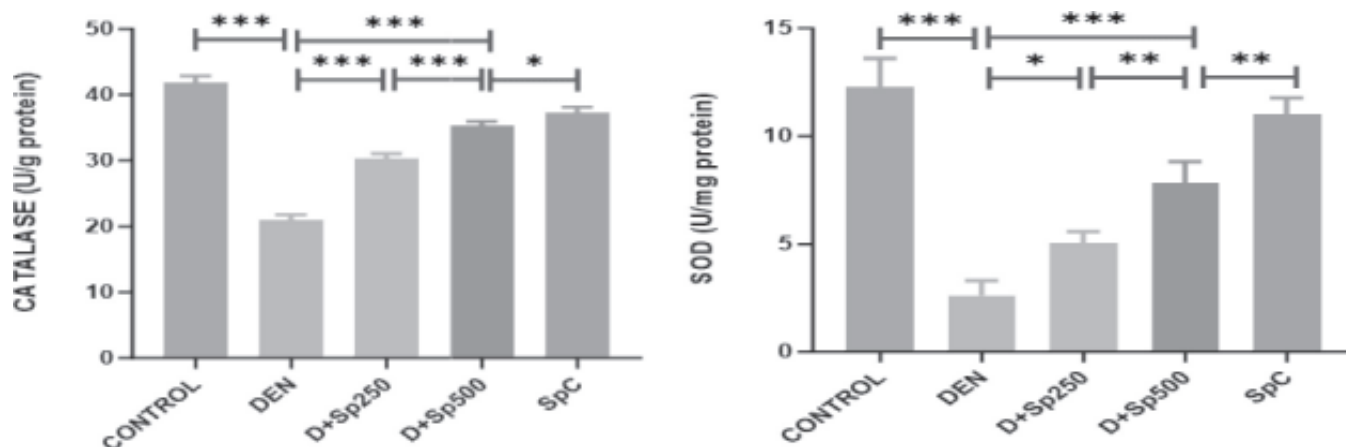


Fig. 2 : The antioxidant marker enzymes such as Superoxide dismutase (SOD), Catalase (CAT), and stress marker Lipid peroxidation were tested in the all the experimental group animals. The results were evaluated by using 1-way ANOVA Analysis was performed using GraphPad prism software 10.0. Values are reported as mean \pm SEM (n = 7) and similar results were obtained in two independent experiments. Statistical significance was defined as *P<0.05, **P<0.01, ***P<0.001, with respect to Control vs DEN+CCl₄, DEN+CCl₄ vs D+Sp250, DEN+CCl₄ vs D+Sp500, D+Sp250 vs D+Sp500, D+Sp500 vs SpC group.

and pronounced congestion of blood sinusoids. Several beneficial effects on the liver tissue were seen as a result of the treatment of SP. These benefits included a minor enlargement of the sinuses, a reduction in the number of cancer lesions, mild to moderate vascular degeneration, and apoptosis of the hepatocytes (Fig. 3). In most cases, the histological alterations demonstrated an improvement in the groups which were treated with SP. Additionally, a larger dose of SP led to a better recovery when compared to a lesser dose of *Spirulina*. The SP control group had a liver architecture that was normal.

Discussion

This study reveals that SP has a chemoprotective impact against liver cancer caused by DEN+CCl₄. Currently there are no drugs in the market that can provide complete protection or aid in the regeneration of liver cells³. This is despite the fact that there have been major developments in modern medicine. Further, there are some drugs that have the potential to cause unpleasant responses. Therefore, it is of the utmost importance to investigate substitutive natural substances for the therapeutics of liver diseases that have a high effectiveness and a lower threshold of toxicity.

Injecting DEN has been shown to result in the generation of free radicals, which alter antioxidant levels and contribute to oxidative stress and carcinogenesis⁹. This has been proved by a number of studies. Damage to the liver comes about as a consequence of the presence of DEN, which leads to an unstable metabolism in the liver and significant changes in the activity of blood enzymes¹⁴. Both DEN and CCl₄ are responsible for the

damage that they produce to the liver, which is a consequence of increased lipid peroxidation (LPO) during their metabolic processes and a reduction in the synthesis of antioxidant enzymes¹⁹. Lipid peroxides have a deleterious effect on the DNA of cells, which can result in genetic alterations and the development of cancer. In addition, the antioxidant provides protection against reactive oxygen species (ROS). Additionally, superoxide dismutase (SOD) has the ability to assist the conversion of two superoxide radicals into hydrogen peroxide (H₂O₂) and oxygen (O₂) through a process known as disproportionation. Additionally, by providing support for antioxidant enzymes, CAT makes it easier for hydrogen peroxide (H₂O₂) into water (H₂O)^{16,19}. Other symptoms include high levels of SGOT and SGPT¹¹, as well as various types of tumours²³. Through histological examination of liver tissue, it has been established beyond a reasonable doubt that DEN+CCl₄ has a carcinogenic impact. This study demonstrates the presence of necrotic lesions present in liver cells, that there are varying degrees of steatosis, and numerous vacuoles of diverse sizes present in the hepatocytes³⁹. The current study revealed that the administration of DEN in conjunction with CCl₄ results in a significant increment in the blood activities of GOT, and GPT enzymes, while simultaneously resulting in a decrease in the serum total protein level as compared to mice that were subjected to normal circumstances. These findings indicate that there was damage to the liver (liver injury). Additionally, a significant rise in the amount of MDA is associated with a reduction in the activity of both catalase and superoxide dismutase. Necrosis, widespread vacuolar degeneration of the liver cells,

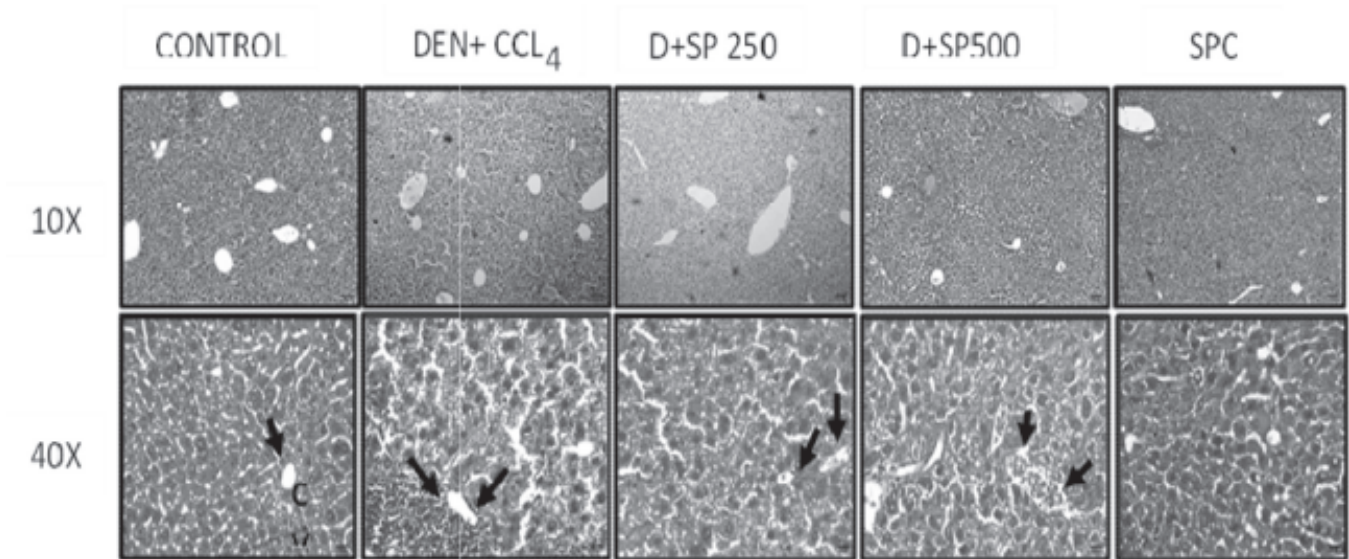


Fig. 3 : Histopathological examine of liver of different groups of mice (Control, DEN+CCl₄, D+Sp250, D+Sp500, SpC group) at 10x and 40x.

strong inflammation with infiltration of mononuclear cells, and the presence of cytoplasmic inclusion bodies were all seen in the group that was treated with DEN+CCl₄ according to the findings of the histological investigation. According to the findings of our research, the administration of spirulina to animals efficiently improves the liver enzyme biomarkers that are affected by the injection of DEN+CCl₄. Compared to mice which were injected with DEN+ CCl₄, animals that were treated with spirulina had lower levels of liver enzymes (AST, ALT, and ALP)⁴⁰. These findings are consistent with the findings of another study that had shown the similar results. It is possible that the antioxidant property of spirulina, which protects liver tissue from degeneration, is responsible for the augmentation of liver enzyme activity that occurs as a result of therapy with spirulina³³. When compared to mice that were injected with DEN+CCl₄, the current findings indicate that treatment with spirulina resulted in a large decrease in MDA levels and a considerable increase in antioxidant activity, notably an increase in SOD and CAT⁵. According to a previous study, which also indicated that supplementation with spirulina led to a substantial increase in CAT and SOD activity, as well as a decline in MDA levels^{26,27}, these findings are consistent with the findings of the current study¹⁶. The hepatoprotective effect of spirulina was demonstrated using histological research, which showed that treatment with SP improved hepatic cancer lesions and decreased the number of hepatocytes that died. One possible

explanation for this is that spirulina possesses antioxidant properties and has the capacity to reduce oxidative stress. An examination using histological techniques demonstrated that the administration of spirulina resulted in an improvement of liver tissue.

Conclusion

Our study has shown that administering a higher dose of Spirulina treatment had a more pronounced hepatoprotective impact against hepatocellular carcinoma (HCC) compared to administering a lower dose of Spirulina treatment. The hepatoprotective effect can be linked to the antioxidant characteristics of the Spirulina, as well as its ability to reduce oxidative stress and its potentiality to downregulate the expression of genes related to cancer progression and inflammation. Based on the interpretation of this study, it is likely that the application of spirulina as a therapeutic agent might prove to be advantageous in the management of the progression of liver cell carcinoma.

Conflict of interest statement.

The authors declare that there is no conflict of interest in the publication of this article. All authors contributed equally to this work.

- This study was supported by the UGC non- NET fellowship.
- Data are available upon request.
- All applicable institutional and/or national guidelines for the care and use of animals were followed.

References

1. Abass SA, Abdel-Hamid NM, Abouzed TK, el-Shishtawy MM. Chemosensitizing effect of *Alpinia officinarum* rhizome extract in cisplatin-treated rats with hepatocellular carcinoma. *Biomed Pharmacother.* 2018; **101** :

2. Abdel-Daim MM, Abuzead SM, Halawa SM. Protective role of *Spirulina platensis* against acute deltamethrin-induced toxicity in rats. *PLoS One*. 2013; **8** : e72991.
3. Aebi H. catalase in vitro. *Methods Enzymol*. 1984; **105** : 121–6.
4. Almatroodi SA, Alsahli MA, Alharbi HM, Husain Rehman A. Epigallocatechin-3- gallate (EGCG), an active constituent of green tea: implications in the prevention of liver injury induced by diethylnitrosamine (DEN) in rats. *Appl Sci*. 2019; **9**(22): 4821.
5. Almatroodi SA, Anwar S, Almatroudi A, Khan AA, Khan AA, Alrumaihi F, Alsahlma, Rahmani AH. Hepatoprotective effects of garlic extract against carbon tetrachloride (CCl₄)-induced liver injury via modulation of antioxidant, antiinflammatory activities and hepatocyte architecture. *Appl Sci*. 2020; **10**(18) : 6200.
6. Amin A, Hamza AA, Bajbouj K, Ashraf SS, Daoud S. Saffron: a potential candidate for a novel anticancer drug against hepatocellular carcinoma. *Hepatology*. 2011; **54**(3) : 857–67.
7. Ande SR, Nguyen KH, Grégoire Nyomba BL, Mishra S. Prohibitin-induced, obesity-associated insulin resistance and accompanying low-grade inflammation causes NASH and HCC. *Sci Rep*. 2016; **6** : 1–12.
8. Angulo P. Nonalcoholic fatty liver disease. *N Engl J Med*. 2002; **346** : 1221–31.
9. Bancroft J, Layton C, Suvarna S. Bancroft's Theory and Practice of Histological Techniques, 7th edn. NY, USA: Churchill Livingstone, 2013.
10. Brown NS, Bicknell R. Hypoxia and oxidative stress in breast cancer oxidative stress-its effects on the growth, metastatic potential and response to therapy of breast cancer. *Breast Cancer Res*. 2001; **3** : 1–5.
11. Bulle F, Mavier P, Zafrani ES et al. Mechanism of α -glutamyl transpeptidase release in serum during intrahepatic and extrahepatic cholestasis in the rat: a histochemical, biochemical and molecular approach. *Hepatology*. 1990; **11** : 545–50.
12. Chamorro G, Salazar M, Araújo KG, dos Santos CP, Ceballos G, Castillo LF. Update on the pharmacology of spirulina (*Arthrospira*), an unconventional food. *Arch. Latinoam Nutr*. 2002; **52**(3) : 232–40.
13. Chatterjee T. Handbook of Laboratory Mice and Rats. Department of Pharmaceutical Technology, Jadavpur University, 1993, 157.
14. Deshwal N, Sharma AK, Sharma P. Review on hepatoprotective plants. *Int J Pharm Sci Rev Res*. 2011; **7** : 15–26.
15. Elaidy SM, Moghazy A, El-Kherbetawy MK. Evaluation of the therapeutic effects of Polyvinylpyrrolidone-capped silver nanoparticles on the Diethylnitrosamine/carbon tetrachloride induced hepatocellular carcinoma in rats. *Egyptian Journal of Basic and Clinical Pharmacology (EJBPCP)*. 2017; **7** : 9–24.
16. El-Tantawy WH. Antioxidant effects of spirulina supplement against lead acetate-induced hepatic injury in rats. *J Tradit Complement Med*. 2016; **6** : 327–31.
17. Fu Y, Chung F-L. Oxidative stress and hepatocarcinogenesis. *Hepatoma Res*. 2018; **4** : 39.
18. Gantar M, Dhandayuthapani S, Rathinavelu A. Phycocyanin induces apoptosis and enhances the effect of topotecan on prostate cell line LNCaP. *J. Med. Food*. 2012; **15** : 1091– 1095.
19. Gey K. Prospects for the prevention of free radical disease, regarding cancer and cardiovascular disease. *Br Med Bull*. 1993; **49** : 679–99.
20. Gornall AG, Bardawill CJ, David MM. Determination of serum protein by means of the biuret reagent. *J Biol Chem*. 1949; **177** : 751.
21. Grawish ME. Effects of *Spirulina platensis* extract on Syrian hamster cheek pouch mucosa painted with 7, 12-dimethylbenz [a] anthracene. *Oral Oncol*. 2008; **44** : 956–62.
22. Hamzawy MA, El-Denshary ES, Abdel-Wahhab MA. Effects of natural compounds in treatment and prevention of hepatotoxicity and hepatocellular carcinoma. *Hepatoma Res*. 2015; **1** : 111–8.

23. Hassan HA, El-Gharib NE, Azhari AF. Role of natural antioxidants in the therapeutic management of hepatocellular carcinoma. *Hepatoma Res.* 2016; **2** : 216–23.
24. Ismail MF, Ali DA, Fernando A, abdraboh ME, Gair RL, Ibrahim WM, Ray MH, Ouhtit A. Chemoprevention of rat liver toxicity and carcinogenesis by spirulina. *Int J Biol Sci.* 2009; **5**(4) : 377.
25. Jemal A, Bray F, Center MM. Global cancer statistics. *CA Cancer J Clin.* 2011; **61** : 69–90.
26. Khan Z, Bhadouria P, Bisen P. Nutritional and therapeutic potential of spirulina. *Curr Pharm Biotechnol.* 2005; **6** : 373–9.
27. Mahmoud YI, Shehata AMM, Fares NH, Mahmoud AA. Spirulina inhibits hepatocellular carcinoma through activating p53 and apoptosis and suppressing oxidative stress and angiogenesis. *Life Sci.* 2021; **265** : 118827.
28. Marquardt J, Galle P, Teufel A. Hepatocellular carcinoma: molecular pathogenesis and novel targets for therapy. *Dtsch Med Wochenschr.* 2012; **137** : 855–60.
29. Nishikimi M, Rao NA, Yagi K. The occurrence of superoxide anion in the reaction of reduced phenazine methosulfate and molecular oxygen. *Biochem Biophys Res Commun.* 1972; **46** : 849–54.
30. Ohkawa H, Ohishi N, Yagi K. Assay for lipid peroxides in animal tissues by thiobarbituric acid reaction. *Anal Biochem.* 1979; **95** : 351–8.
31. Polimeni L, Del Ben M, Baratta F, Perri L, Albanese F, Pastori D, Violi F, Angelico F. Oxidative stress: new insights on the association of non-alcoholic fatty liver disease and atherosclerosis. *World J Hepatol.* 2015; **7**(10) : 1325.
32. Poon D, Anderson BO, Chen LT, Tanaka K, Lau WY, Van Cutsem EE, Singh H, Chow WC, Ooi L, Chow P, Khin MW, Koo WH. Management of hepatocellular carcinoma in Asia: consensus statement from the Asian oncology summit 2009. *Lancet Oncol.* 2009; **10**(11) : 1111–1118.
33. Ramakrishnan G, Augustine TA, Jagan S, Vinod Kumar R, Devaki T. Effect of silymarin on N-nitrosodiethylamine induced hepatocarcinogenesis in rats. *Exp Oncol.* 2007; **29** : 39–44.
34. Reitman S, Frankel S. A colorimetric method for the determination of serum glutamic oxalacetic and glutamic pyruvic transaminases. *Am J Clin Pathol.* 1957; **28** : 56–63.
35. Sasaki Y. Does oxidative stress participate in the development of hepatocellular carcinoma? *J Gastroenterol.* 2006; **41** : 1135–48.
36. Srivastava A, Shivanandappa T. Hepatoprotective effect of the root extract of *Decalepis hamiltonii* against carbon tetrachloride-induced oxidative stress in rats. *Food Chem.* 2010; **118** : 411–7.
37. Tabone M, Pellicano R. Prevention of intrahepatic hepatocarcinoma recurrence in patients with viral cirrhosis: two potential options. *Minerva Gastroenterol Dietol.* 2006; **52** : 47–52.
38. Talari M, Seydi E, Salimi A, Mohsenifar Z, Kamalinejad M, Pourahmud J. Dracocephalum: novel anticancer plant acting on liver cancer cell mitochondria. *Biomed Res Int.* 2014; **89** : 21–70.
39. Vásquez-Garzón VR, Arellanes-Robledo J, García-Román R et al. Inhibition of reactive oxygen species and pre-neoplastic lesions by quercetin through an antioxidant defense mechanism. *Free Radic Res.* 2009; **43** : 128–37.
40. Whittby L, Perey-Robb I, Smith A. Enzymes Tests in Diagnosis, Lecturer Notes in Clinical Chemistry. London: Black Well Scientific Publications, 1984.
41. Yamada KI, Yamamiya I, Utsumi H. *In vivo* detection of free radicals induced by diethylnitrosamine in rat liver tissue. *Free Radic Biol Med.* 2006; **40** : 2040–6.